

Sonographic Assessment of Some Abdominal Organs in Children with Sickle Cell Disease in Ilorin, Nigeria

Basirat Muftaudeen^{1*}, Joseph C. Eze², Muhammad Sidi³, Mutiat Nike Muftaudeen⁴

¹Department of Radiology, University of Ilorin Teaching Hospital, Ilorin, Kwara State, Nigeria, ²Department of Radiology and Radiological Sciences, Nnamdi Azikwe University, Nnewi Campus, Nnewi, Nigeria, ³Department of Radiography, Bayero University Kano, Kano, Nigeria, ⁴Department of Radiotherapy, Usmanu Dan Fodio University Teaching Hospital, Sokoto, Nigeria

Abstract

Background: The irregular sickle cells can block blood vessels, causing tissue and organ damage and in most cases presented with pain as a result of organ ischemia. Ultrasonography is an easily available instrument for investigating abdominal organs which are most commonly affected by sickle cell disease (SCD). This study was aimed to assessing liver, gall bladder, spleen, and kidney in children with SCD in Ilorin, Kwara State. **Methods:** A prospective cross-sectional study was conducted among children with SCD in Ilorin from September 2017 to April 2018. An ethical approval was obtained from the Human Research and Ethics Committee of the Kwara State Ministry of Health. In this study, 106 children with SCD and 106 normal children for control were included. Abdominal ultrasound scan was performed on all the selected subjects and the findings were recorded on the data capture sheet. Descriptive and inferential statistic was used in the data analysis, SPSS version 20 was used and the $P=0.05$. **Results:** In the children with SCD, hepatomegaly was found in 45 (42.5%), 29 (27.4%) had coarse echo pattern of liver and 16 (15.1%) had hyperechoic liver, 5 (4.7%) had gallbladder stone, 2 (1.9%) had gallbladder sludge, and 6 (5.6%) had thickened gallbladder wall. Twenty-five (23.6%) had splenomegaly, and 7 (6.6%) had autosplenectomy. Four (3.8%) showed reduced corticomedullary differentiation in each kidney, five (4.7%) in each kidney had mild calyceal dilatation. One (0.9%) had mild calyceal dilatation with reduced corticomedullary differentiation with accompanying loss of renal sinus fat. **Conclusion:** Abdominal ultrasound imaging for patients with SCD showed a high incidence of abdominal abnormalities, especially in solid organs such as liver, kidney, and spleen.

Keywords: Sickle cell, ultrasonography, Ilorin

INTRODUCTION

Sickle cell disease (SCD) is a disorder of the blood caused by inherited abnormal hemoglobin called sickle hemoglobin in the red blood cells. This causes the red blood cells to be distorted (sickle). The sickle red blood cells are fragile and prone to rupture; hemolysis; which leads to anemia. When a person has two hemoglobin S (HbS) genes, Hemoglobin SS (homozygous sickle cell) is the most common and often most severe kind of SCD. Hemoglobin SC disease and hemoglobin S β thalassemia are two other common forms of SCD.^[1] United Nations estimates that there are between 20 and 25 million people worldwide living with SCD, of which 12–15 million live in Africa.^[2]

The most common organs involved during crisis are spleen, liver, biliary tract, and kidneys. Although gastrointestinal tract and adrenals may sometimes be affected, the percentage is very low. Crises mainly affect the homozygous sickle cell patient and rarely affect those with heterozygous hemoglobin.^[3] There is frequent hepatic dysfunction associated with crises in SCD. Hepatic dysfunctions include unexplained hepatic necrosis, portal fibrosis, regenerative nodules, and cirrhosis. They are usually as a consequence of recurrent vascular obstruction, necrosis, and repair.^[4] The spleen has a combined function of immune defense and quality control of altered red

Address for correspondence: Mrs. Basirat Muftaudeen, C/O Alhaji Toyin, No. 25 Jabata Compound, Princess Road, Ilorin, Kwara State, Nigeria. E-mail: apeke90@gmail.com

Received: 03-04-2020 Revised: 29-04-2020 Accepted: 14-07-2020 Available Online: 01-10-2020

Access this article online

Quick Response Code:



Website:
www.jmuonline.org

DOI:
10.4103/JMU.JMU_47_20

This is an open access journal, and articles are distributed under the terms of the Creative Commons Attribution-NonCommercial-ShareAlike 4.0 License, which allows others to remix, tweak, and build upon the work non-commercially, as long as appropriate credit is given and the new creations are licensed under the identical terms.

For reprints contact: WKHLRPMedknow_reprints@wolterskluwer.com

How to cite this article: Muftaudeen B, Eze JC, Sidi M, Muftaudeen MN. Sonographic assessment of some abdominal organs in children with sickle cell disease in Ilorin, Nigeria. *J Med Ultrasound* 2021;29:94-8.

cells. It is the first organ injured in sickle cell anemia (SCA) with evidence of hyposplenism present before 12 months after birth in the majority of children. Repeated splenic vaso-occlusion leads to fibrosis and progressive atrophy of the organ (autosplenectomy), which is generally completed by 5 years in the SCD.^[5]

Ultrasound is a safe and noninvasive imaging modality that is used in the diagnosis of pathological conditions involving abdominal organs.^[6] A study conducted by Oguntoye *et al.*^[7] on hepatobiliary ultrasonographic abnormalities in adult patients with SCA in steady state in Ile-Ife, Nigeria, among 50 SCA and 50 age- and sex-matched subjects with HbAA as controls. The result shows that among the patients, 32 (64%) had hepatomegaly, 15 (30%) cholelithiasis, and 3 (6%) biliary sludge. Fourteen (28%) of the patients had normal hepatobiliary ultrasound findings. In a prospective study conducted by Mohanty *et al.*^[3] on the sonological assessment of abdominal organ in sickle cell crisis in Western Orisa, India, fifty patients of SCD were scanned, they found thus; hepatomegaly (72%), splenomegaly (64%) and cholelithiasis (22%). Splenic infarction was found in 22% of the patients, 10% of the patients showed splenic calcification. Increased bilateral renal echogenicity was observed in 16% of patients. In the ideal practice, every locality should have a documented work of abdominal findings of patients with SCD, but to our best knowledge there is no documented work in Ilorin Kwara State. The findings of our study are expected to serve as a guide for the practitioners in the management of children with SCD in Ilorin, Kwara State.

MATERIALS AND METHODS

The study was a prospective cross-sectional conducted among children with SCD in Ilorin from September 2017 to April 2018. An ethical approval to conduct the study was obtained from the Human Research and Ethics Committee of the Kwara State Ministry of Health. (IRB number: MOH/KS/EU/777/192). Written informed consent from the children's parents or guardians were all obtained. In this study, 106 were children with SCD, while 106 were children with homogeneous normal (AA) genotype as controls. The ultrasound examinations were performed with the children in the supine position for optimal visualization of the liver, gallbladder, the kidneys, and the spleen. The right and left oblique position and also prone position were used as alternate positions if the organs were not clearly visualized in the supine position. The liver span was measured in the right lobe with longitudinal views taken in the midclavicular and midline positions, and measurements obtained. Anterior-posterior diameters were also measured at the midpoint of the longitudinal diameter,^[8] and the thickness was obtained by measuring on the transverse view [Figure 1]. The gallbladder, longitudinal and transverse measurements were taken from a subcostal or an intercostal approach on deep inspiration in the supine positions,^[8] its wall thickness normally <3 mm, and content was also assessed [Figure 2]. Splenic measurement

was obtained from a coronal plane that included the hilum. The greatest longitudinal distance between the splenic dome and the tip (splenic length) was measured [Figure 3]. Transverse, longitudinal, and diagonal diameters are measured from the image showing a maximum cross-sectional area in a coronal plane.^[8] When the spleen was not visualized in its position, it was defined as autosplenectomy.^[9,10] When the long axis of the spleen was >120 mm in children older than 10 years and >110 mm for children from 1 to 10 years, it was defined as splenomegaly.^[8] A shrunken spleen was defined when the long axis of the organ was <30 mm. The spleen was also assessed for parenchymal echotexture changes and focal abnormalities. The length of the kidneys was obtained by measuring the bipolar length (long axis) of the kidneys [Figure 4]. The upper limit for normal right and left kidneys sizes among school age children (6–12 years) were 79.6 ± 8.1 mm and 81.6 ± 8.3 mm respectively.^[10] The kidneys were considered abnormally echogenic if the renal cortex was equal to or more echogenic than adjacent spleen or liver. The measurements obtained from the study group were compared with those obtained from the control group. The evaluation of the echotexture of the organs was done subjectively in the gradation of the echo textural changes in accordance with the grading pattern of Shetty and Radswiki^[11] who categorized the echogenicity of abdominal organs starting from the diaphragm being more

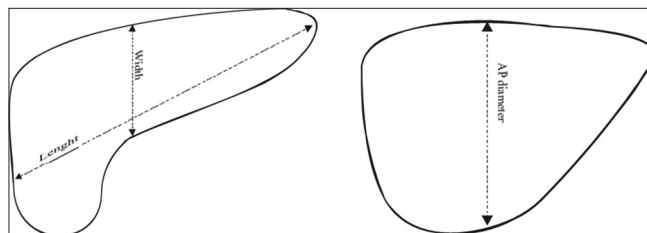


Figure 1: Sketch diagram showing measurement of the liver

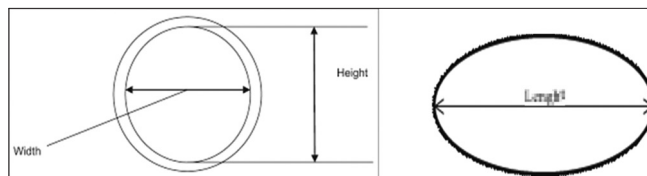


Figure 2: Sketch diagram showing measurement of the gallbladder

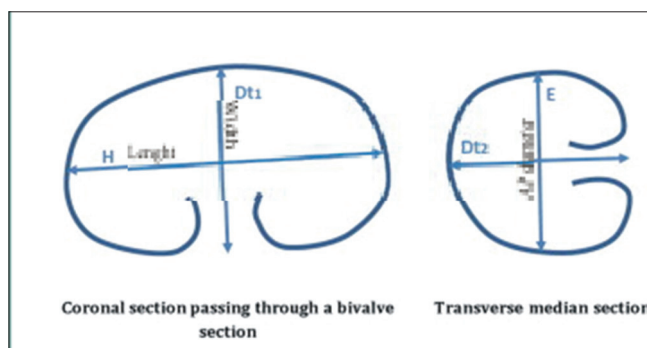


Figure 3: Sketch diagram showing measurement of the kidney

echogenic than the pancreas, the pancreas is more echogenic than the spleen, the spleen is more echogenic than the liver and the liver is more echogenic than the kidneys. The organ size, echotexture, echogenicity, and any other pathology found in the organ were recorded, also the age and gender were recorded. The height, weight, and body mass index (BMI) of the children were also measured using standard procedures and recorded in the data capture sheet. The volume of the organs was calculated using the standard formula for calculating volume; volume = length \times width \times AP diameter \times 0.52.^[12] Data were analyzed using Statistical Package for Social Sciences version 20.0 (IBM SPSS [2011], version 20.0. Armonk, NY, USA: IBM Corp.). The mean, standard deviation, and range were obtained using descriptive statistics. Comparison of the mean values of the abdominal organs among children with SCD and controls was obtained using independent two sample *t*-test. The relationship between the Pearson correlation analysis was used to establish relationships between the organs size and demographic variables was obtained using Pearson's correlation. The preset *P* = 0.05.

RESULTS

The age range of the children was between 1 and 16 years with a mean age of 6.1 ± 3.2 and 6.58 ± 4.1 for the AA genotype children and the children with SCD, respectively. The height, weight and BMIs of the control group were 0.7–1.55 m (1.13 ± 0.17), 9–43 kg (21 ± 7), and 10.1–19.8 (16.1 ± 1.9) respectively, while height was 0.67–1.55 m (1.11 ± 0.2), weight 9–38 kg (19 ± 8), and BMI is 10.1–20.7 (15.18 ± 2.2) for the SCD children.

DISCUSSION

The findings of the study show that the complications are more prevalent among the older children 9–16 years of age, also the findings are in agreement with that of the studies conducted by Mohanty *et al.*^[3] Ma'aji *et al.*^[13] The possible reason might be as a result of repeated crisis from a young age that leads to more complications as the children grow older. The findings of this study imply that thorough routine examination should be carried out in grown up children suffering from SCD. Among the children with SCD, the most common sonographic abnormality found in the liver was hepatomegaly, followed by coarse echogenicity of liver and increase echogenicity of the liver as shown in Table 1. The findings are in accordance with

the findings of the studies conducted by Ma'aji *et al.*^[13] Luntsi *et al.*^[14] This may be due to the fact that the liver is the site of metabolism of most drugs used in the management of the SCD, also repeated vascular occlusion and blood transfusions can also cause more complications to the liver. Infiltrative and

Table 1: The liver sonographic findings

Variables	Participant		
	Control (%)	SCD (%)	Total (%)
Liver size pattern			
Normal size	99 (93.4)	61 (57.5)	160 (75.5)
Slightly enlarged (140-160 mm)	0	6 (5.7)	6 (2.8)
Markedly enlarged (>160 mm)	7 (6.6)	39 (36.8)	46 (21.7)
Echotexture/echogenicity			
Normal echogenicity and homogenous	99 (93.4)	57 (53.8)	156 (73.5)
Coarsened only	4 (3.8)	29 (27.4)	33 (15.6)
Hyperechoic only	3 (2.8)	16 (15.1)	19 (9.0)
Hypoechoic only	0	1 (0.9)	1 (0.5)
Coarsened and hyperechoic	0	3 (2.8)	3 (1.4)

SCD: Sickle cell disease

Table 2: Gallbladder appearance and wall thickness

Variables	Control group (AA) (%)	SCD (%)	Total (%)
Gallbladder appearance			
Clear echoluscent content	103 (97.2)	99 (93.4)	202 (95.3)
Gallstone presents	0 (0.0)	5 (4.7)	5 (2.4)
Sludge present	3 (2.8)	2 (1.9)	5 (2.4)
Gallbladder wall thickness			
Normal wall thickness (<3 mm)	104 (98.1)	100 (93.7)	204 (96.2)
Thickened wall	2 (1.9)	6 (5.7)	8 (3.8)

SCD: Sickle cell disease

Table 3: The splenic sonographic findings

Variables	Participants		
	Control group (AA) (%)	SCD (%)	Total (%)
Spleen size pattern			
Normal size	103 (97.2)	57 (53.8)	160 (75.5)
Reduced in size	0 (0.0)	17 (16.0)	17 (8.0)
Totally absent	0 (0.0)	7 (6.6)	7 (3.3)
Splenomegaly	3 (2.8)	25 (23.6)	28 (13.2)
Echotexture/echogenicity			
Normal echogenicity and homogenous	105 (99.1)	78 (73.6)	183 (86.3)
Coarse	1 (0.9)	22 (20.7)	23 (10.9)
Coarse with micro calcifications	0 (0.0)	6 (5.7)	6 (2.8)

SCD: Sickle cell disease

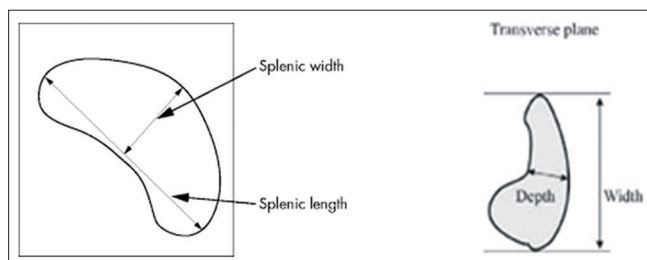


Figure 4: Sketch diagram showing measurement of the spleen

granulomatous diseases, infections, malignancy, and other hematologic diseases may also cause hepatomegaly Mohanty *et al.*;^[3] Rusheke.^[15] In the control group, the gallbladder was found to be normal in all except three (2.8%) of them who have sludge in their gallbladder as shown in Table 2, this may be due to restricted diets that may cause the bile to stay for too long in the gallbladder or effect of any medication. Thickened gallbladder wall was seen in six (5.7%) of the patient with SCD, gall stone was present in five (4.7%) of them, gallbladder sludge was seen in two (1.9%) of them as shown in Table 2. This is most probably as a result of the increased load of bile salts resulting from the shortened lifespan of the blood cells containing HbS. This is similar to previous studies carried out by Bharati *et al.*;^[16] Balci *et al.*;^[17] Luntsi *et al.*^[14] In the control group, it was found that only three (2.8%) of them have splenomegaly, and one (0.9%) have coarsened and hyperechoic spleen as shown in Table 3. This could have been caused by, malaria, trauma to the spleen, causing hematoma, or inflammatory bowel diseases. Splenomegaly was the most common splenic abnormality found among the SCD patients. Previous studies conducted by Ma'aji *et al.*;^[13] Bharati *et al.*;^[16] Luntsi *et al.*;^[14] also reported splenomegaly as the most common splenic abnormality. Causes of splenomegaly include

acute splenic sequestration, infectious or granulomatous disease, malignancy, and other hematologic diseases. Autosplenectomy was seen in seven of SCD children, there was marked reduction in splenic size in eight of them as shown in Table 3. Autosplenectomy has been previously reported as one of the common findings in SCD patients Babadoko *et al.*;^[9] Ma'aji *et al.*;^[13] Bharati *et al.*;^[16] Al-Saleem *et al.*^[18] This is commonly caused by repetitive sickling of red blood cells in the splenic microcirculation which leads to splenic infarction, progressing over time to autosplenectomy. SCD is associated with many structural and functional abnormalities of the kidney, which may progress to chronic renal failure and end-stage renal disease Luntsi *et al.*^[14] However, in this study, the majority of the children have normal right and left kidney 97 (91.5%) and 96 (90.6%), respectively, as shown in Table 3. This is in agreement with a study conducted by Mohanty *et al.*;^[3] Luntsi *et al.*^[14] Four (3.8%) of them shows reduced corticomedullary differentiation only, five (4.7%) of them have mild calyceal dilatation in both kidneys as shown in Table 4. This is similar to a study conducted by Luntsi *et al.*;^[14] Ma'aji *et al.*^[13] The few that has renal abnormalities may be probably due to acute papillary necrosis (coagulative necrosis of the papillae), or focal pyramidal changes due to ischemia in SCD

Table 4: The kidney sonographic findings

Variables	Participants			
	Control group (AA) (%)		SCD (%)	
	Right kidney	Left kidney	Right kidney	Left kidney
Normal with good corticomedullary differentiation and intact sinus fat	102 (96.2)	104 (98.1)	97 (91.5)	96 (90.6)
Reduced corticomedullary differentiation with loss of sinus fat	0 (0.0)	0 (0.0)	4 (3.8)	4 (3.8)
Mild calyceal dilatation	1 (0.9)	1 (0.9)	5 (4.7)	5 (4.7)
Calyceal dilatation with reduced corticomedullary differentiation and loss of sinus fat	3 (2.8)	1 (0.9)	0 (0.0)	1 (0.9)

SCD: Sickle cell disease

Table 5: Comparison of the mean volume of organs between the control group children and the sickle cell disease children

Mean organ volume (cm ³)	Participants		P
	Control group	SCD	
Liver volume	527.5±572.6	609.8±366.99	0.58
Spleen	72.5±50.63	121.5±101.55	0.76
Gallbladder	5.21±2.04	5.33±2.73	0.80
Right kidney	63.7±17.01	71.15±24.00	0.40
Left kidney	66.2±17.43	71.10±26.16	0.46

SCD: Sickle cell disease

Table 6: Correlation between organ mean volume with age, weight and height in children with sickle cell disease

	Mean volume	Correlation (r)		
		Age, r (P)	Weight, r (P)	Height, r (P)
Liver	609.8±366.99	0.48 (<0.001)	0.39 (<0.001)	0.42 (<0.001)
Spleen	121.5±101.55	0.49 (<0.001)	0.37 (<0.001)	0.48 (<0.001)
Gallbladder	5.33±2.73	0.63 (<0.001)	0.59 (<0.001)	0.58 (<0.001)
Right kidney	71.15±24.00	0.26 (0.007)	0.18 (0.068)	0.22 (0.026)
Left kidney	71.10±26.16	0.75 (<0.001)	0.67 (<0.001)	0.68 (<0.001)

patients. A general increase in organ sizes among SCD patients compared to that of the controls ($P < 0.05$) is shown in Table 5. These findings agree with the result from the previous studies Eze *et al.*^[10] Luntsi *et al.*,^[14] Rusheke^[15] who found a significant difference between the organ sizes among the control group and that of the SCD children ($P < 0.05$). This is generally due to the complications associated with the disease as a result of the sickling of the blood cells. There is a significant positive relationship between the Liver volume and patient's age, height and weight; $r = 0.48$, $r = 0.418$ and $r = 0.395$ respectively, each with a P value = 0.000. Comparing with the spleen; the age, weight and height all shows significant positive relationship with the patient splenic volume, $r = 0.489$, 0.366 and 0.404 respectively, each with a P value = 0.000 [Table 6].

CONCLUSION

Abdominal ultrasound imaging of children with SCD showed a high incidence of abdominal abnormalities, especially in solid organs such as liver, kidney, and spleen. Early detection of these abnormalities will help in children management to prevent further deterioration of the organs.

Financial support and sponsorship

Nil.

Conflicts of interest

There are no conflicts of interest.

REFERENCES

1. National Heart, Lung and Blood Institute. What is Sickle Cell Disease? 2016. Available from: <https://www.nhlbi.nih.gov/health/health-topics/topics/sca>. [Last accessed on 2017 May 20].
2. Aliyu ZY, Kato GJ, Taylor JT, Babadoko A, Mamman AI, Gordeuk VR, *et al.* Sickle cell disease and pulmonary hypertension in Africa: A global perspective and review of epidemiology, pathophysiology, and management. *Am J Haematol* 2008;83:63-70.
3. Mohanty J, Narayan J, Bhagat S, Panda B, Satpathi G, Saha N. Sonological evaluation of abdominal organs in sickle cell crisis in Western Orissa. *Indian J Radiol Imaging* 2004;14:247-51.
4. Bauer TW, Moore W, Hutchins GM. The liver in sickle cell disease: A clinicopathologic study of 70 patients. Department of Pathology of the Johns Hopkins Medical Institutions, Baltimore, Maryland, USA. *Am J Med* 1980;69:833-7.
5. Brousse V, Buffet P, Rees D. The spleen and sickle cell disease: The sick (led) spleen. *Br J Haematol* 2014;166:165-76.
6. Radiologyinfo.org. General Ultrasound; 2016. Available from: <https://www.radiologyinfo.org/en/info.cfm?pg=genus>. [Last accessed on 2018 Jan 07].
7. Oguntoye OO, Ndububa DA, Yusuf M, Bolarinwa RA, Ayoola OO. Hepatobiliary ultrasonographic abnormalities in adult patients with sickle cell anaemia in steady state in ile-ife, Nigeria. *Polish J Radiol* 2017;8:1-8.
8. Paul S, Wui K, Keshtra S. Measurement in Ultrasound; A Practical Guide. Broken Sound Parkway NW: CRC Press Taylor & Francis Group; 2016. p. 4-14.
9. Babadoko AA, Ibinaye PO, Hassan A, Yusuf R, Ijei IP, Aiyekomogbon J, *et al.* Autospelenectomy of sickle cell disease in Zaria, Nigeria: An ultrasonographic assessment. *Oman Med J* 2012;27:121-3.
10. Eze CU, Offordile GC, Agwuna KK, Ocheni S, Nwadike IU, Chukwu BF. Sonographic evaluation of the spleen among sickle cell disease patients in a teaching hospital in Nigeria. *Afr Health Sci* 2015;15:949-58.
11. Shetty A, Radswiki. Abdominal Organ Echogenicity (mnemonic); 2015. Available from: <http://www.Radiopaedia.org>. [Last accessed on 2018 Sep 05].
12. Williams E. The Core Curriculum Ultrasound. Philadelphia, PA: Lippincott Williams & Wilkins; 2001. p. 173.
13. Ma'aji SM, Jiya NM, Saidu SA, Anfulani M, Yunusa GH, Sani UM, *et al.* Transabdominal ultrasonographic findings in children with sickle cell anaemia in Sokoto, North-Western Nigeria. *Niger J Basic Clin Sci* 2012;9:14-7.
14. Luntsi G, Eze CU, Ahmadu MS, Bukar AA, Ochie K. Sonographic evaluation of some abdominal organs in sickle cell disease patients in a tertiary health institution in Northeastern Nigeria. *J Med Ultrasound* 2018;26:31-6.
15. Rusheke AH. Abdominal Ultrasonographic Abnormalities in Patients with Sickle Cell Anaemia at Muhimbili National Hospital. M.Med (Radiology) Dissertation, Muhimbili University of Health and Allied Sciences; 2010.
16. Bharati S, Das S, Majee P, Mandal S. Anesthetic management of a patient with sickle β^+ thalassemia. *Saudi J Anaesthe* 2011;5:98-100.
17. Balci A, Karazincir S, Sangun O, Gali E, Daplan T, Cingiz C, *et al.* Prevalence of abdominal ultrasonographic abnormalities in patients with sickle cell disease. *Diagn Int Radiol J* 2008;14:133-7.
18. Al-Saleem AH, Al-Aithan S, Bhamidipati P, Al Dabbous I. Sonographic assessment of spleen size in Saudi patients with sickle cell disease. *Ann Saudi Med* 1998;18:217-20.